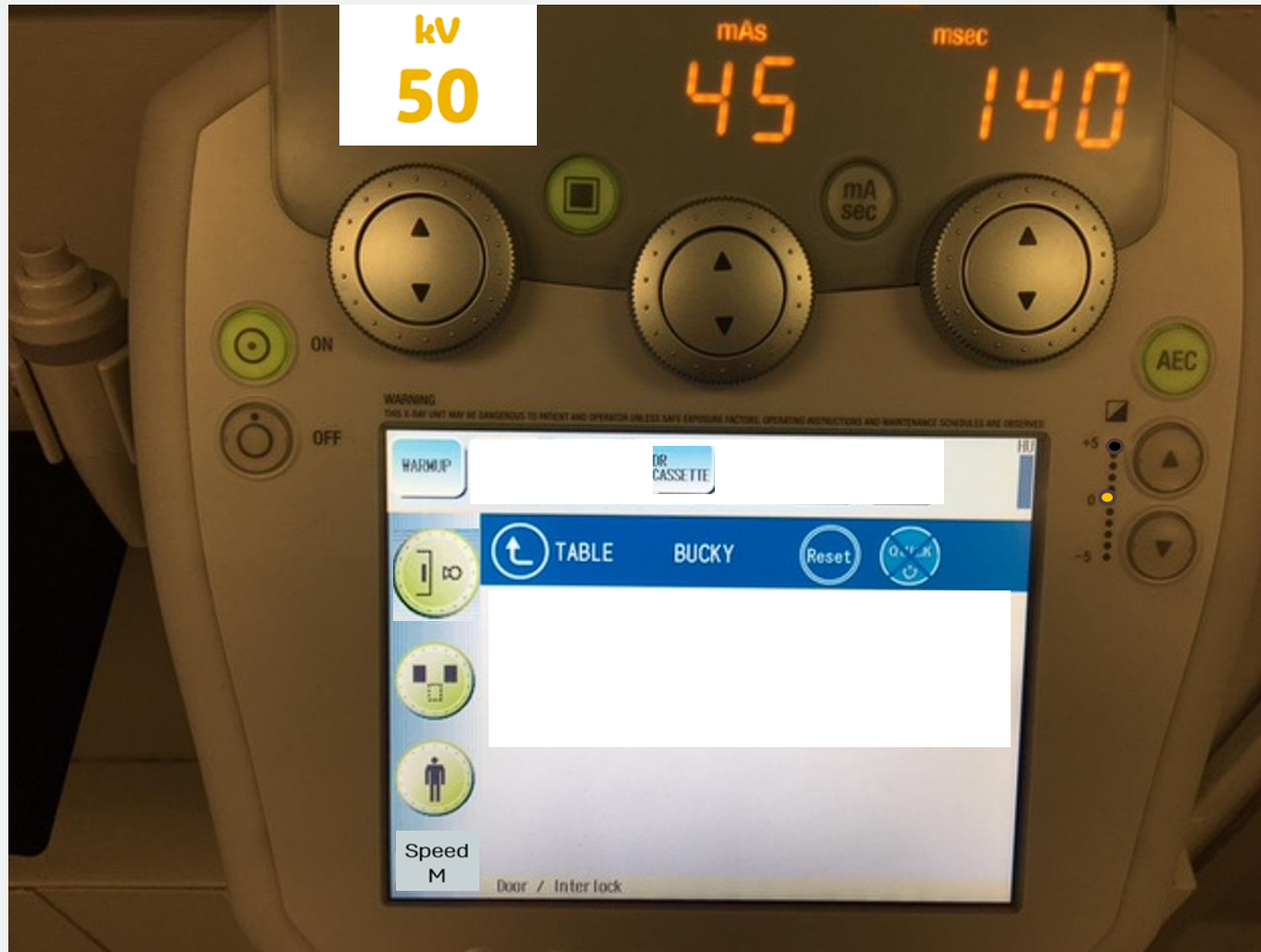


AEC Radiographic Simulations

T-Spine AP (supine)

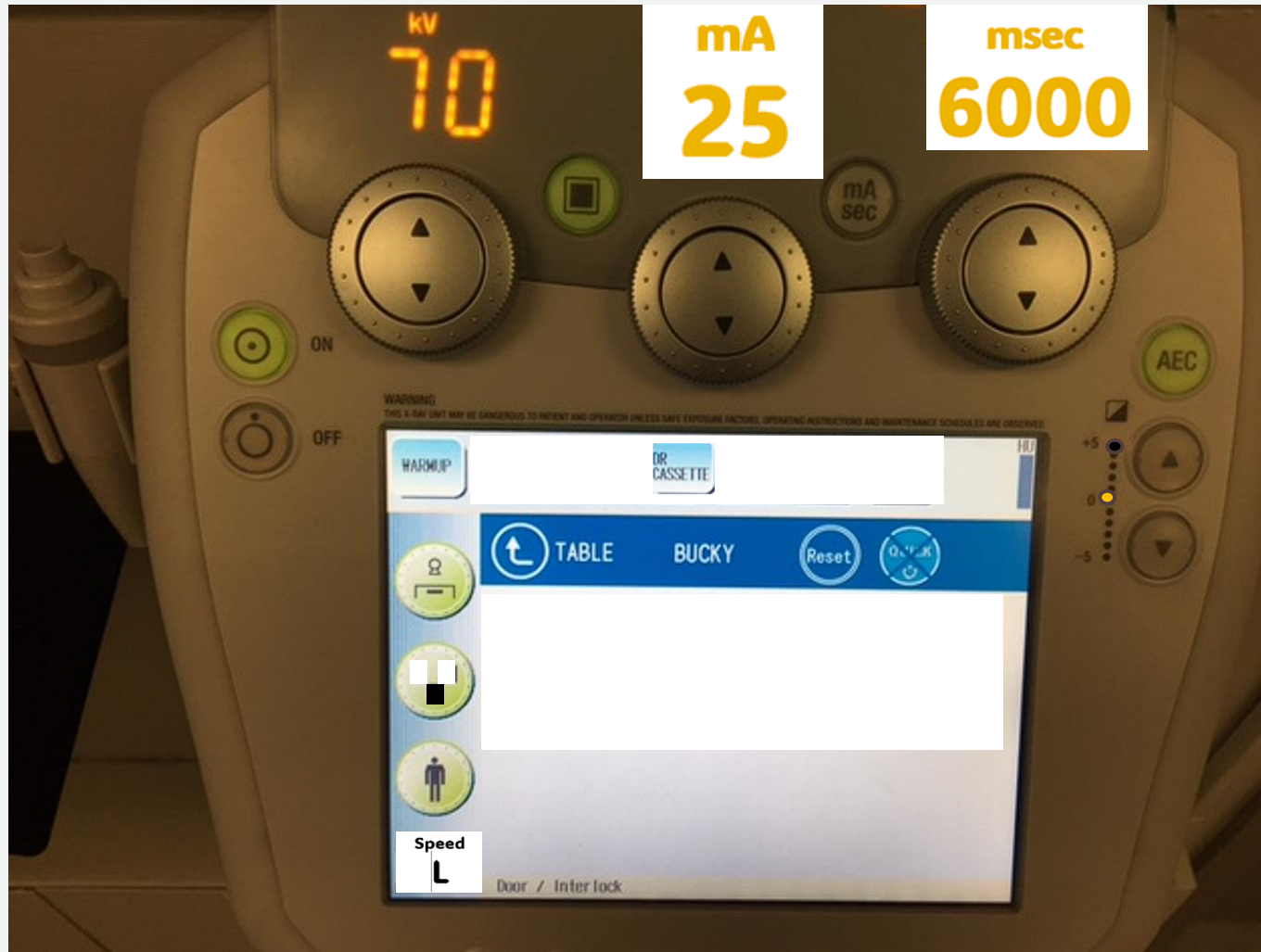Sthenic Patient



Is the setting correct?

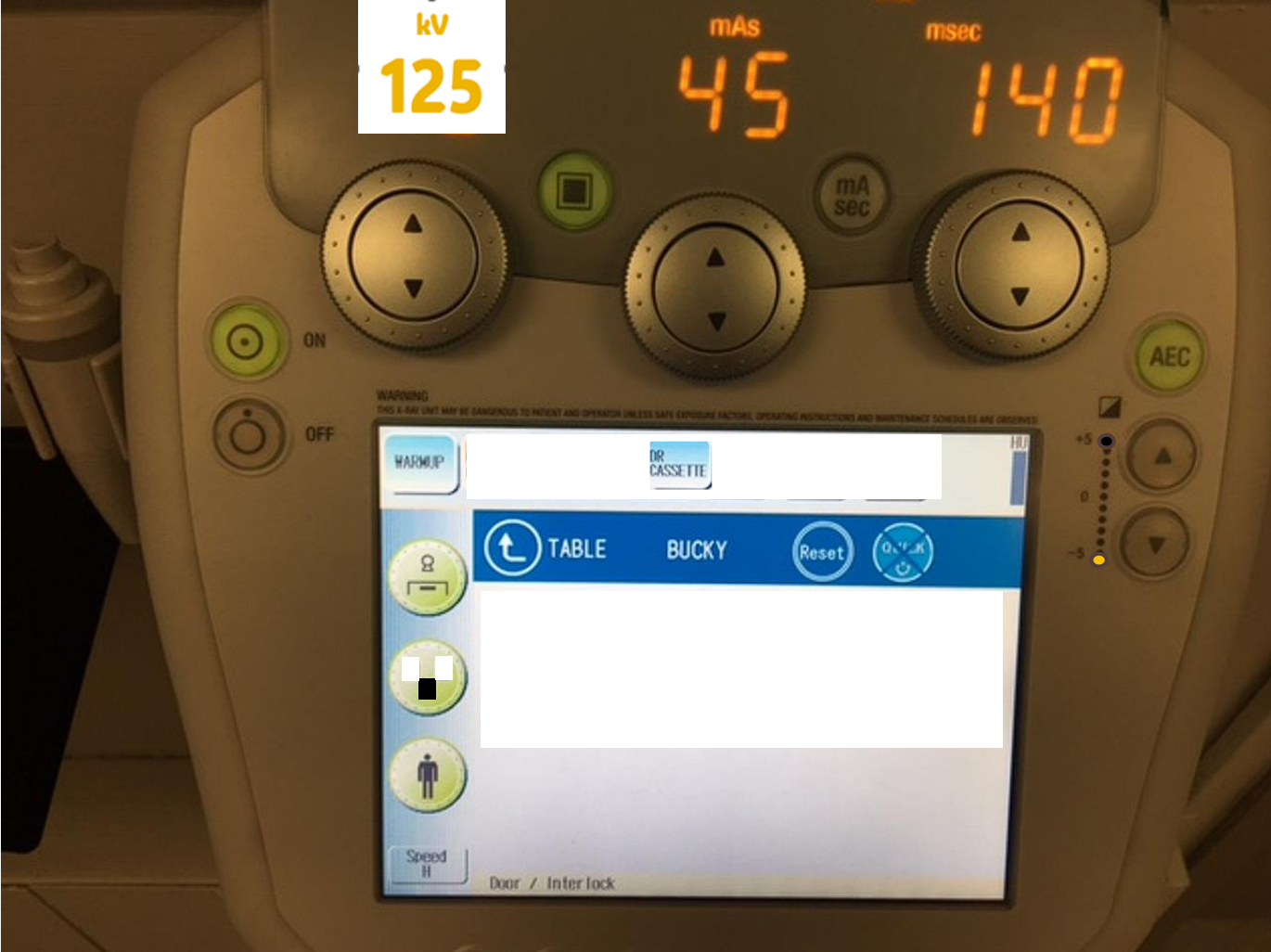
T-Spine Lateral

Sthenic Patient



Is the setting correct?

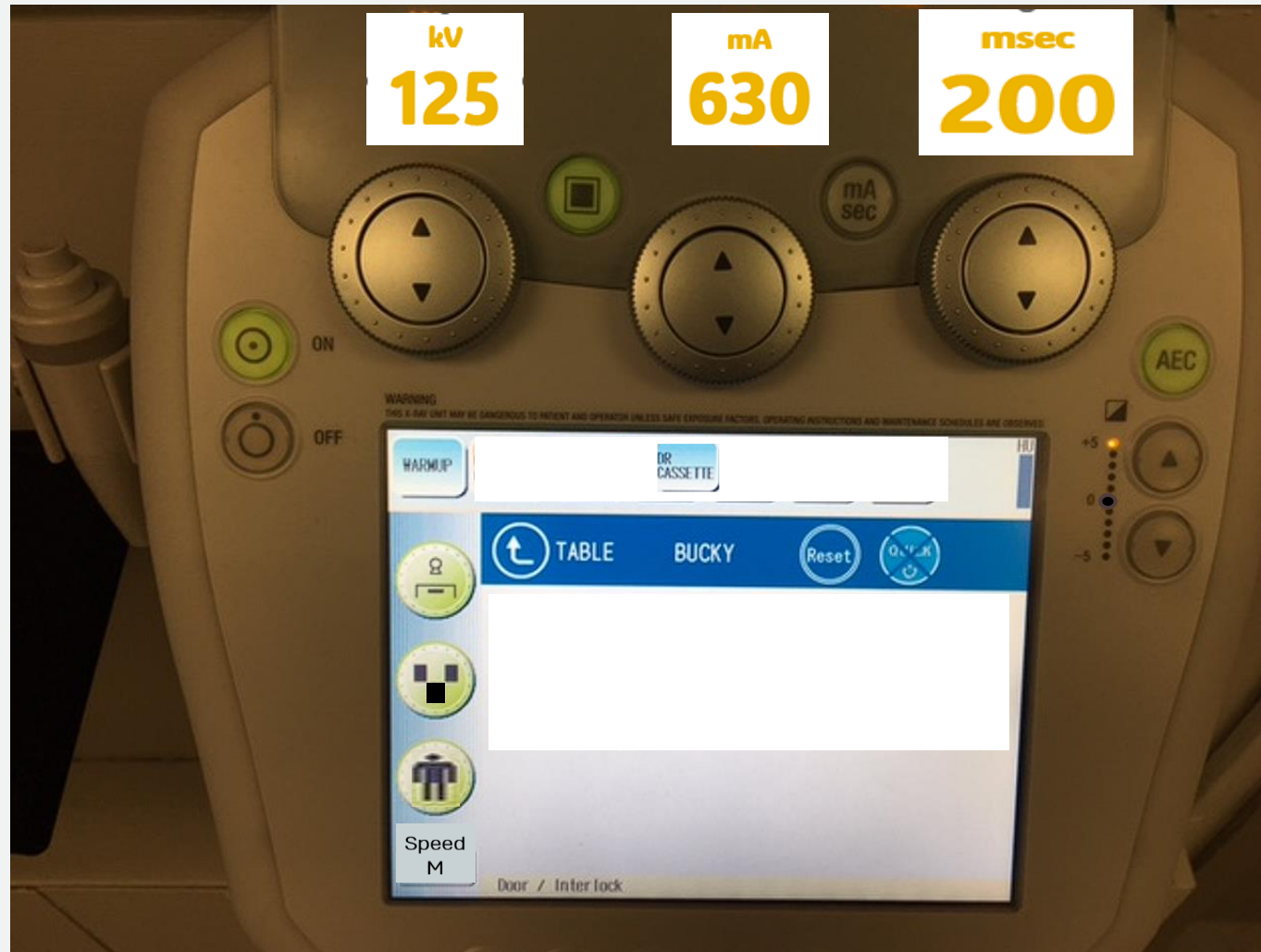Chest AP or PA (Erect) Sthenic Patient



Is the setting correct?

Pelvis AP

Sthenic Patient



Is the setting correct?

Chest AP

Sthenic Patient



Is the setting correct?

Chest Lateral

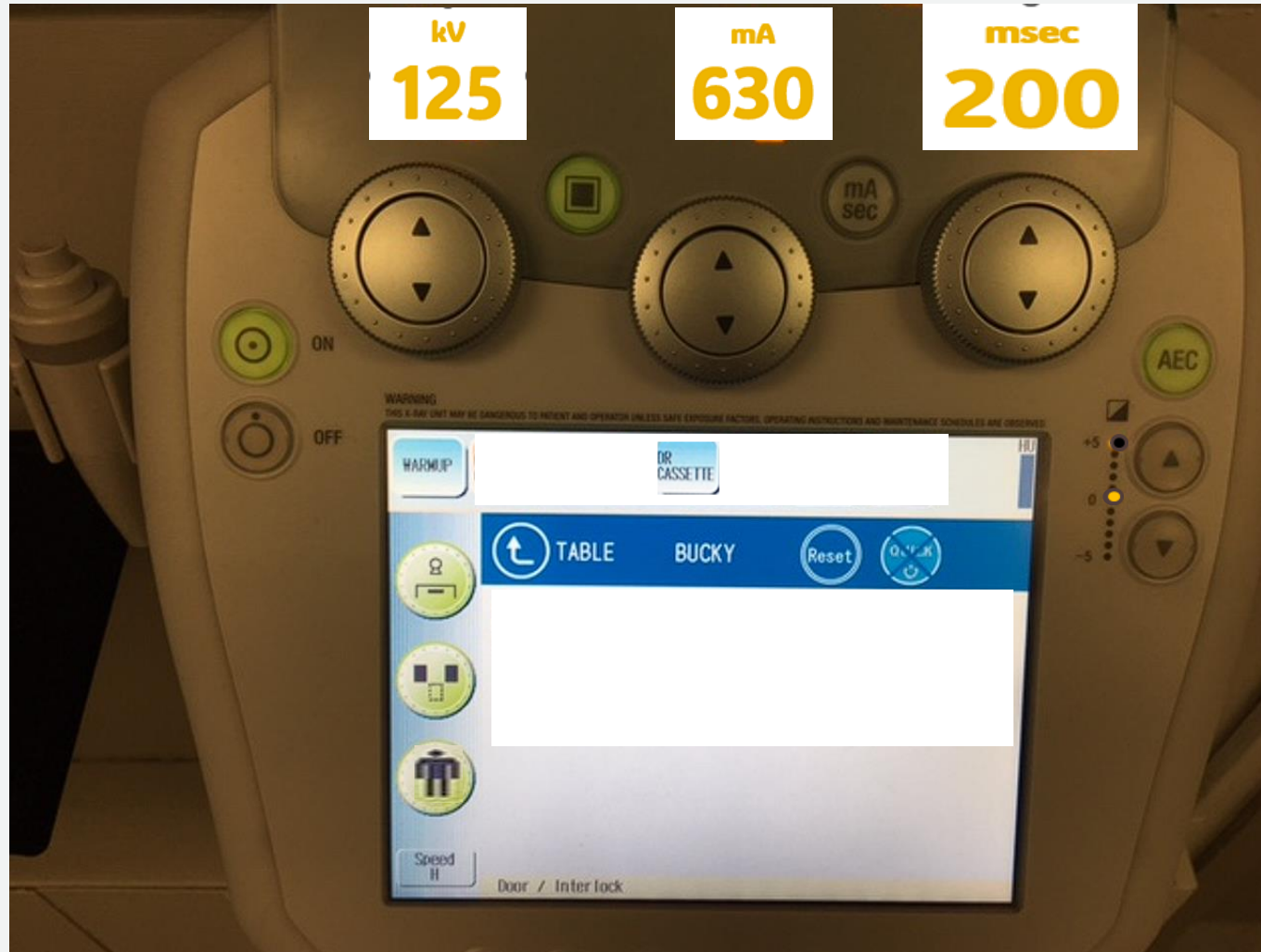
Sthenic Patient

kV
80



Speed
L

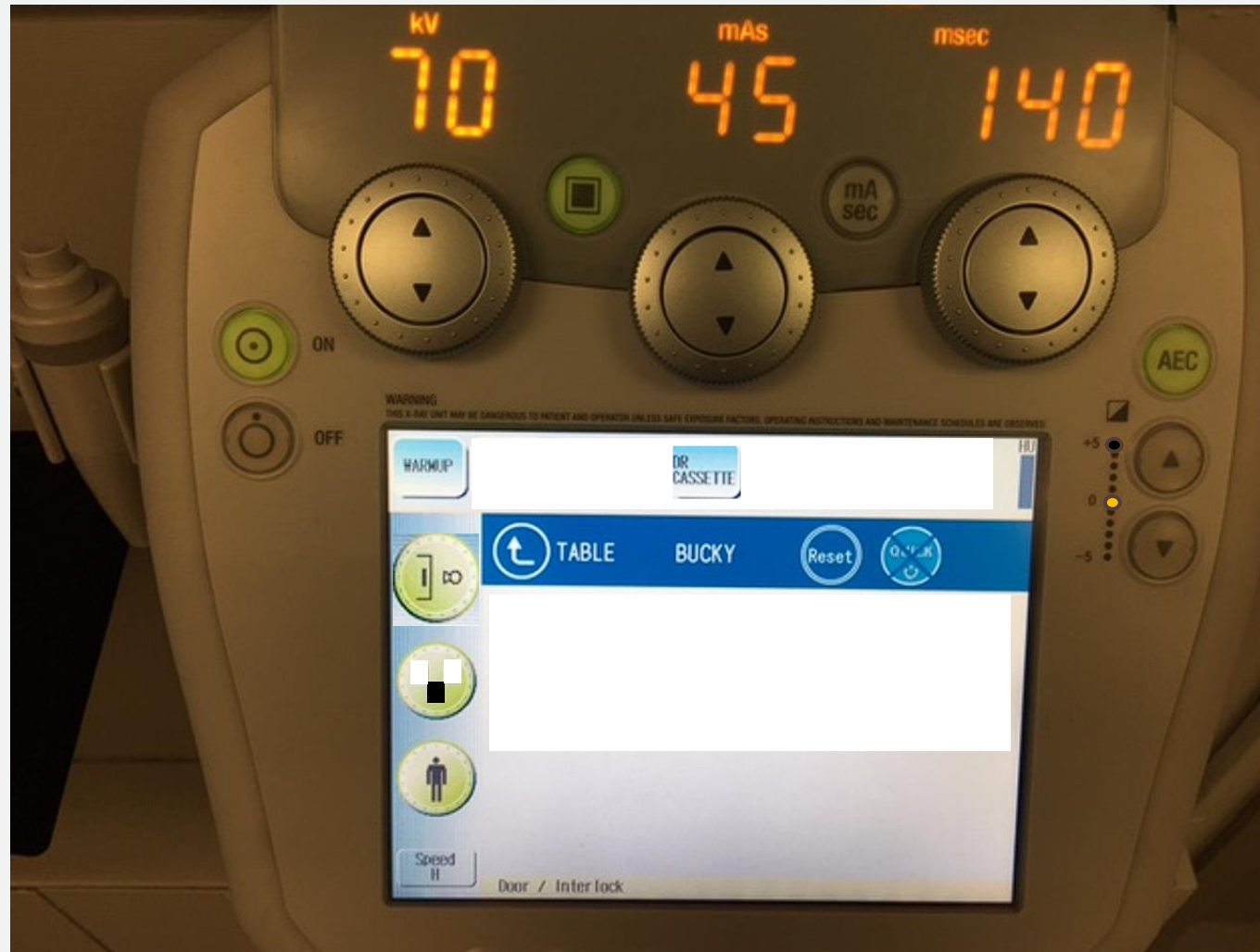
kV
80



Is the setting correct?

Knee AP (supine)

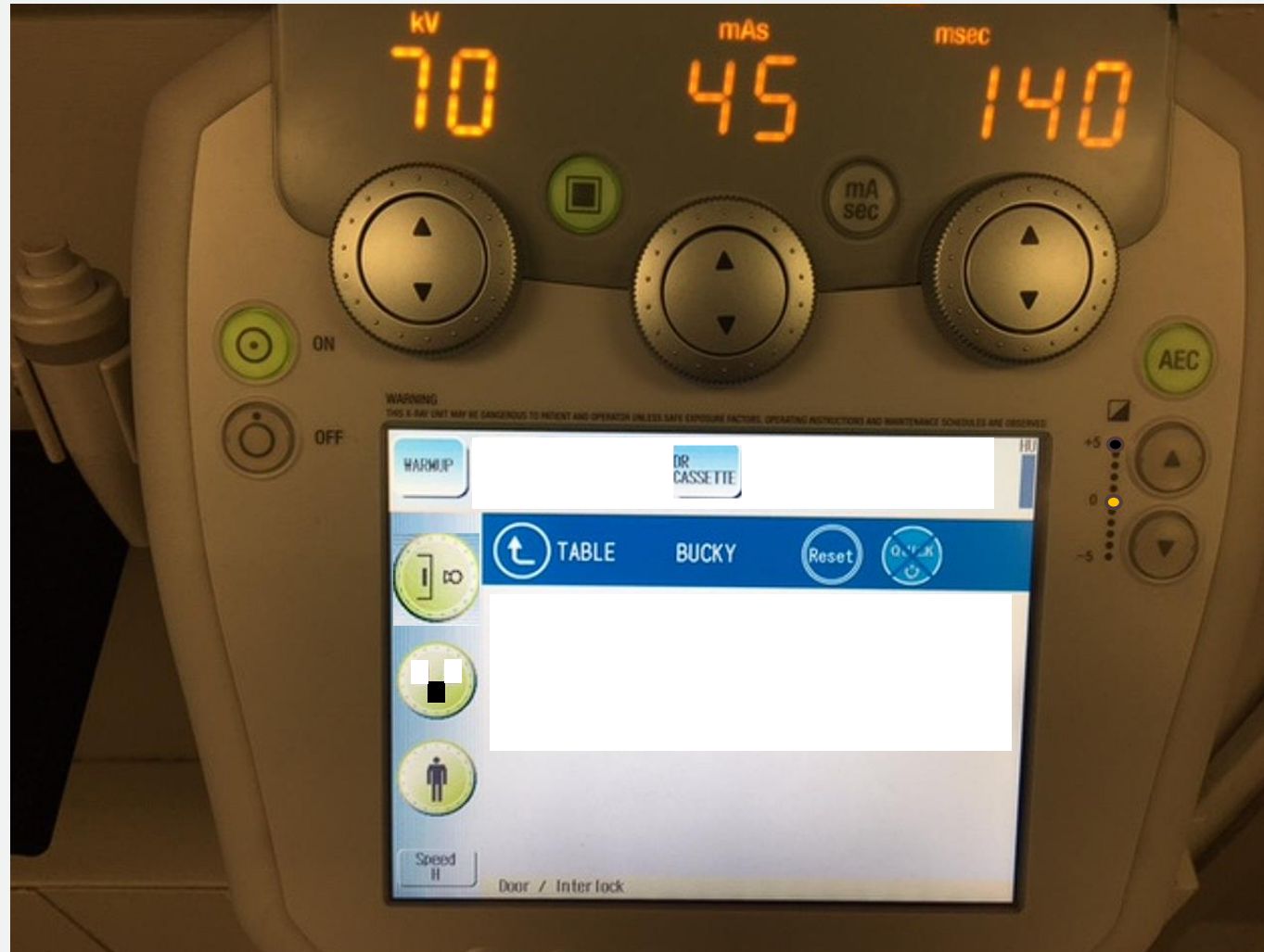
Sthenic Patient



Is the setting correct?

Knee AP (supine) TT


Sthenic Patient



Is the setting correct?

Right Hip AP


Sthenic Patient



Is the setting correct?

PelvisAP

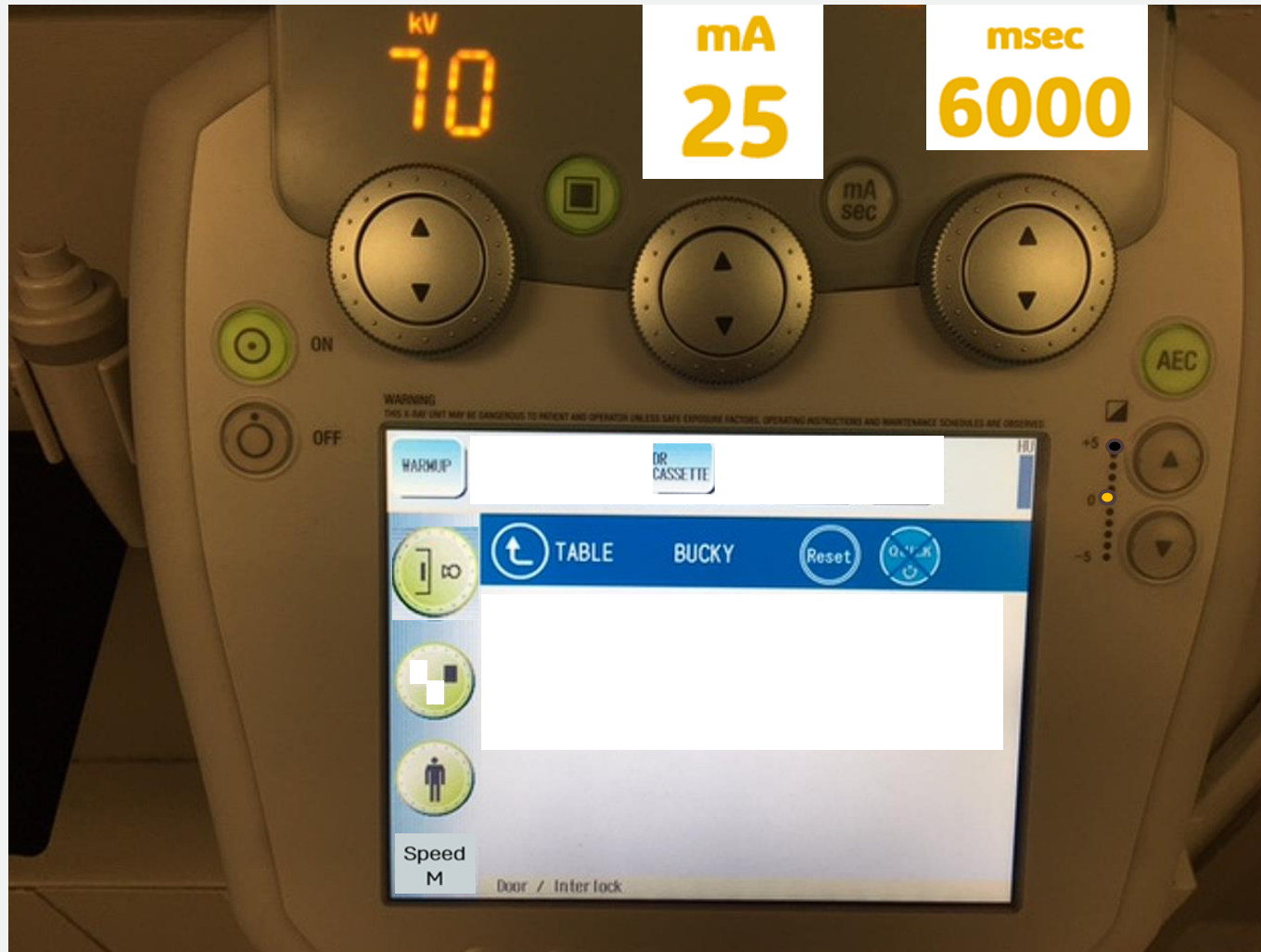
Sthenic Patient



Is the setting correct?

Left Scapula

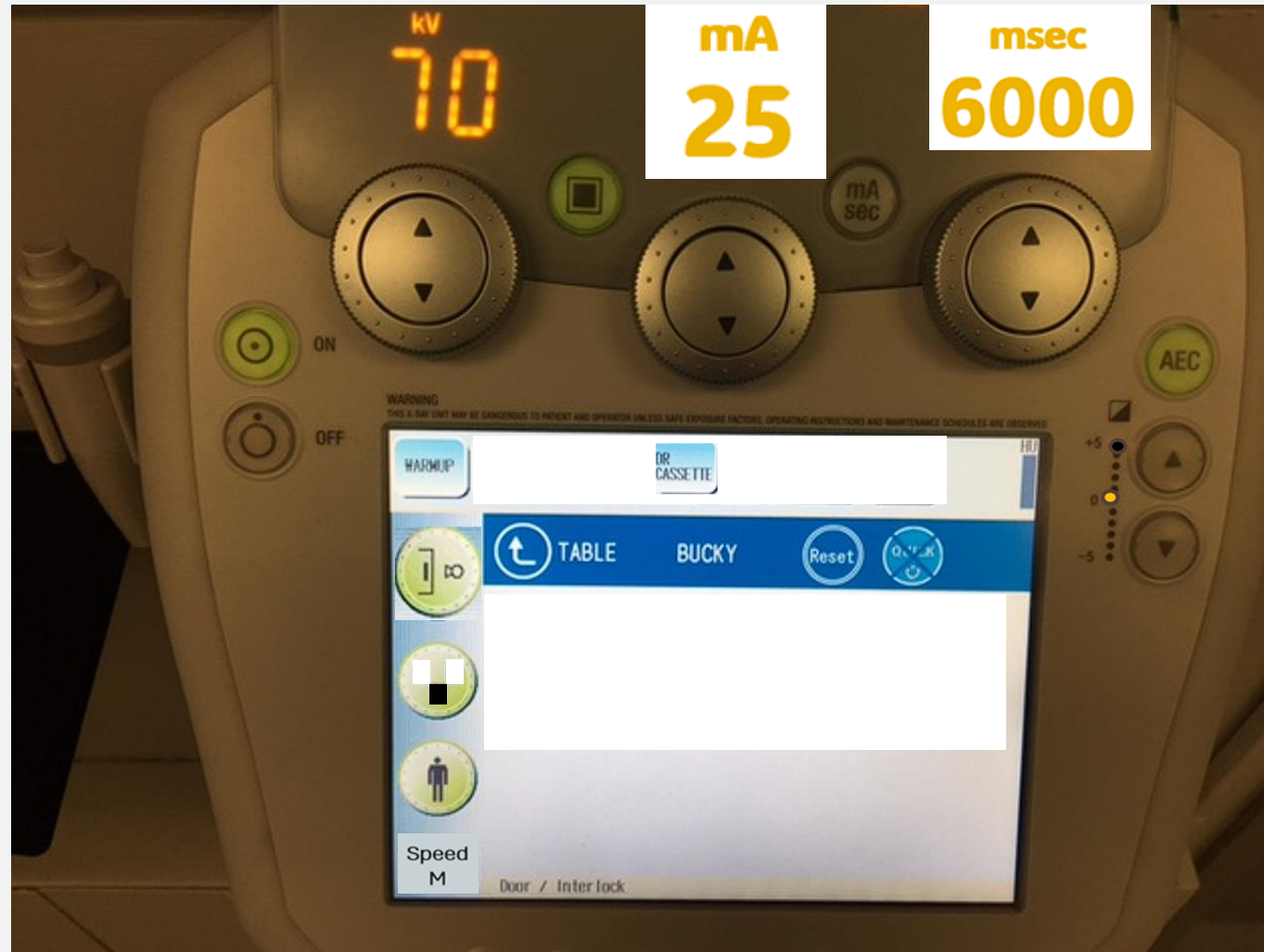Sthenic Patient



Is the setting correct?

Left Scapula (Y view)

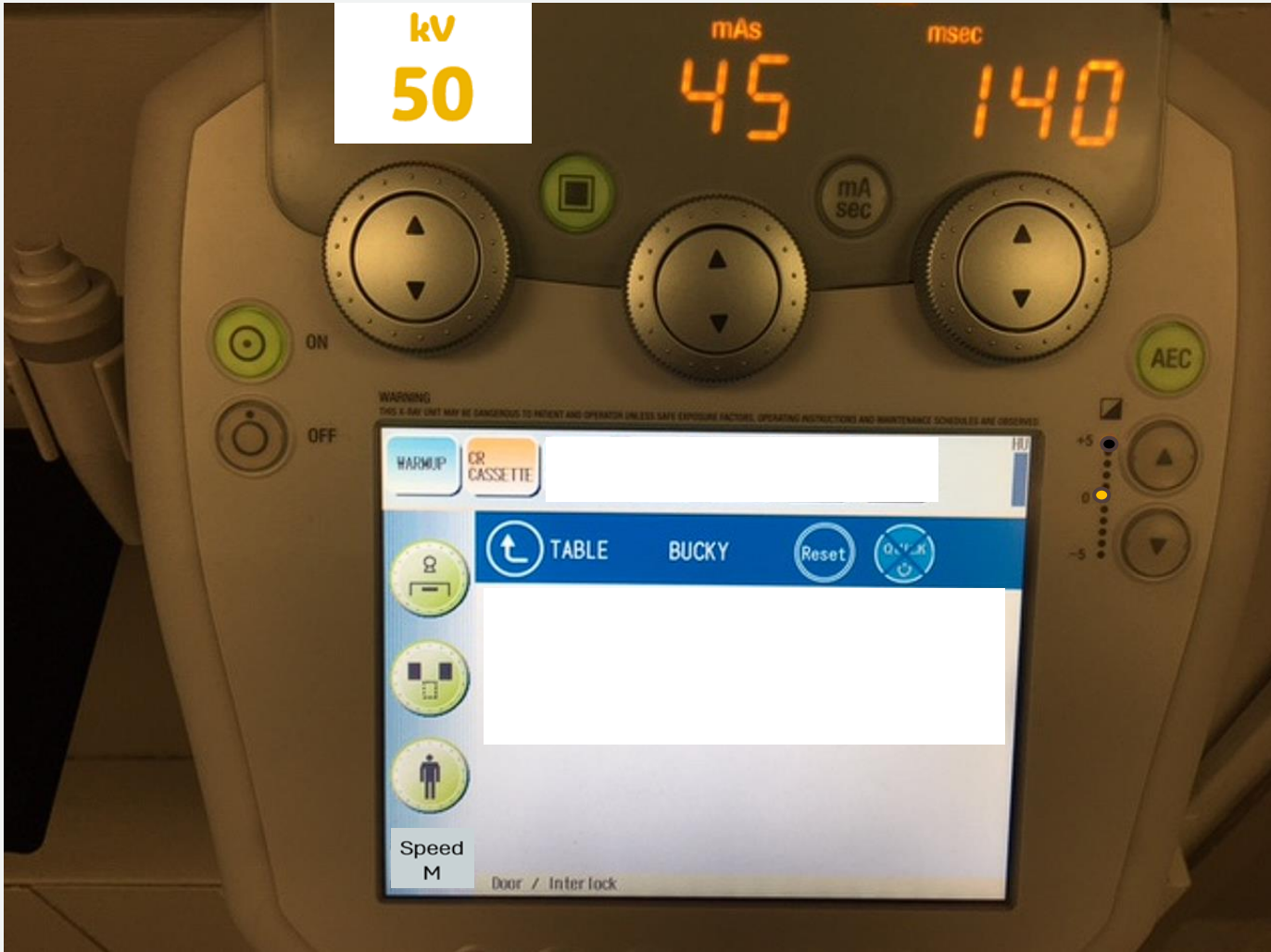Sthenic Patient



Is the setting correct?

C-Spine AP (Erect)

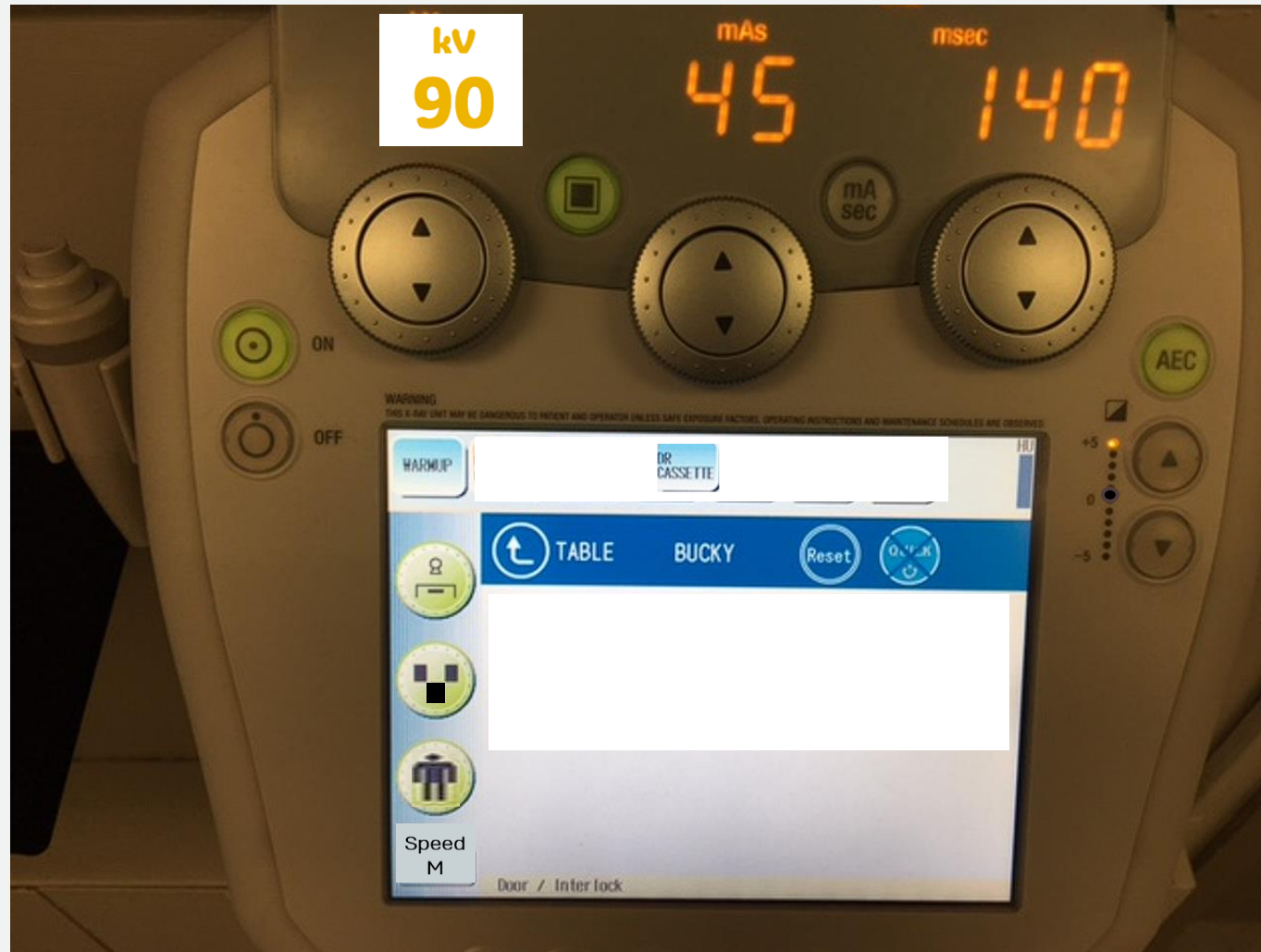
Sthenic Patient



Is the setting correct?

Abdomen (supine) AP

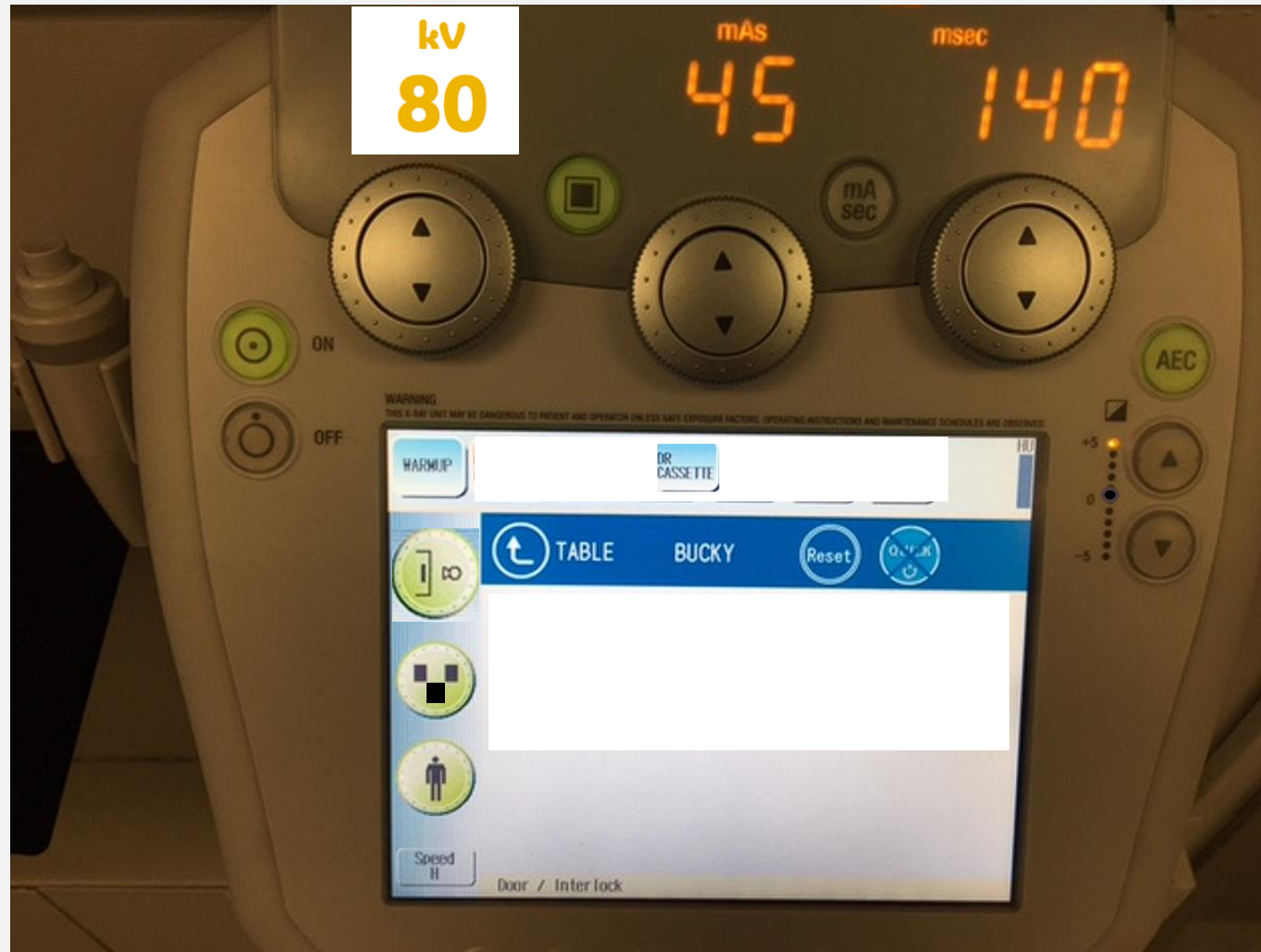
Hypersthenic Patient



Is the setting correct?

Abdomen (supine) AP

Sthenic Patient



Is the setting correct?

