

Lab Experiment # 10

Shape Distortion

DR Lab

Purpose

This experiment is designed to demonstrate the effect of the part–image receptor relationship, central ray–part–image receptor alignment, and central ray direction on shape distortion as well as how each affects sharpness of detail and radiographic quality.

Learning Objectives

After completing this lab, you should be able to:

1. Use the laboratory equipment properly.
2. Set up the control console and ceiling tube mount correctly.
3. Function effectively in group work.
4. Perform the experiment independently.
5. Evaluate the effects of the part–image receptor relationship, central ray–part–image receptor alignment and central ray direction on shape distortion.
6. Describe the relationship between the part–image receptor relationship, central ray–part–image receptor alignment and central ray direction and sharpness of detail.
7. Summarize the part–image receptor relationship, central ray–part–image receptor alignment and central ray direction’s relationships to radiographic quality.
8. Predict the effect of the changes in the part–image receptor relationship, central ray–part–image receptor alignment and central ray direction on shape distortion and radiographic quality.

Materials Needed

- Direct radiography (FPD) digital image receptors
- Whole body phantom
- Set of lead numbers

Maintaining the Proper Central Ray-Part-Image Receptor Alignment

Generally, for the best radiographic quality:

1. The central ray should be ***perpendicular*** to the plane of interest
2. The plane of interest should be ***parallel*** to the plane of the image receptor
3. The part being examined should be ***centered*** to the x-ray beam and ***centered*** to the midpoint of the image receptor, and

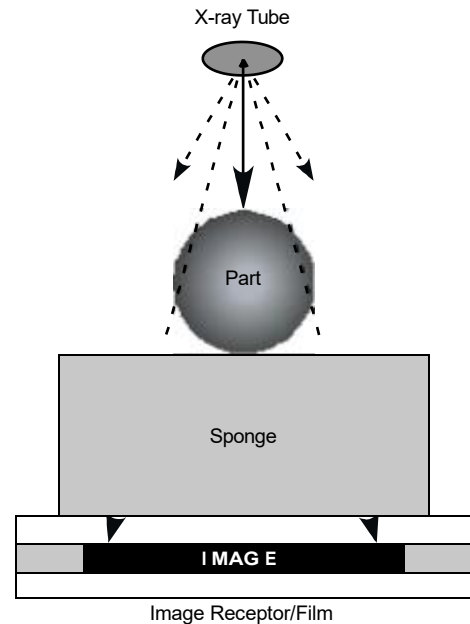
When the central ray ***must*** be angled, the patient's position on the table ***must*** be modified to maintain the proper central ray-part-image receptor alignment.

Perpendicular Central Ray

For routine exams done on the table, the central ray is directed ***vertically***, so that it will be ***perpendicular*** to the image receptor.

In the diagram to the right:

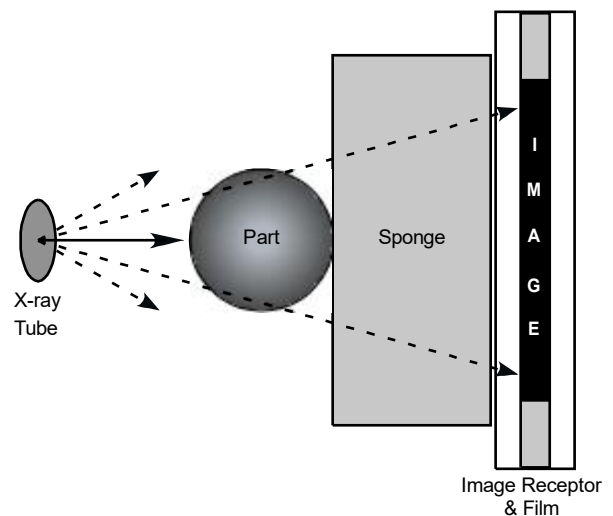
- the central ray is perpendicular
- the part-image receptor relationship is parallel
- the central ray-part-image receptor relationship is centered



For routine upright exams done on the wall unit, the central ray is directed ***horizontally***, so that it will be ***perpendicular*** to the image receptor.

In the diagram to the right:

- the central ray is perpendicular
- the part-image receptor relationship is parallel
- the central ray-part-image receptor relationship is centered



Angled Central Ray – Poorly Positioned

Central ray direction

Whenever the x-ray beam is angled to either the anatomical part or the image receptor, there will be shape distortion.

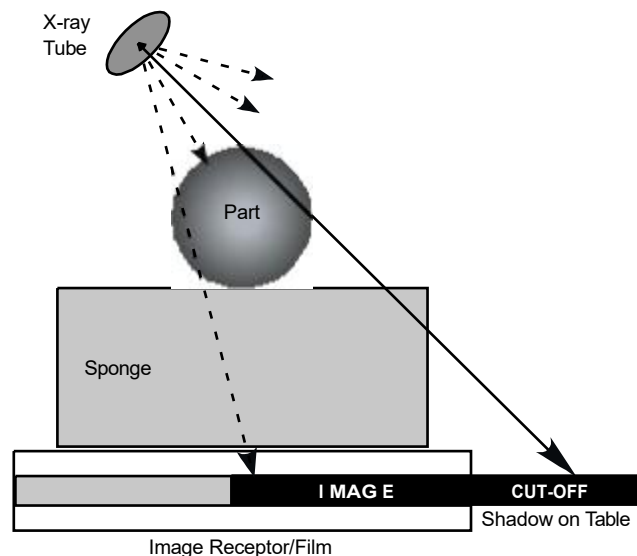
Central ray-part-image receptor alignment

For exams that require a tube angulation special care must be taken. If the central ray is directed to the *same point* on the part that would be used for a perpendicular x-ray beam, it will **NOT** pass through the center of the part **or** the center of the image receptor.

When radiographing smaller objects, a shadow of the part will be projected onto the tabletop; *this represents where the aerial image is being projected*. If the image is being projected past the image receptor, the image will be cut off. The greater the tube angulation, the more detrimental (harmful, damaging) this is.

In the diagram below:

- the central ray is **NOT** perpendicular
- the part-image receptor relationship is **NOT GOOD**
- the central ray-part-image receptor relationship is **NOT GOOD**
- **NO** compensation was made for the central ray angulation; the shadow of the aerial image is **PAST** the image receptor



Angled Central Ray – Properly Positioned

Central ray direction

Whenever the x-ray beam is angled to either the anatomical part or the image receptor, there will be shape distortion.

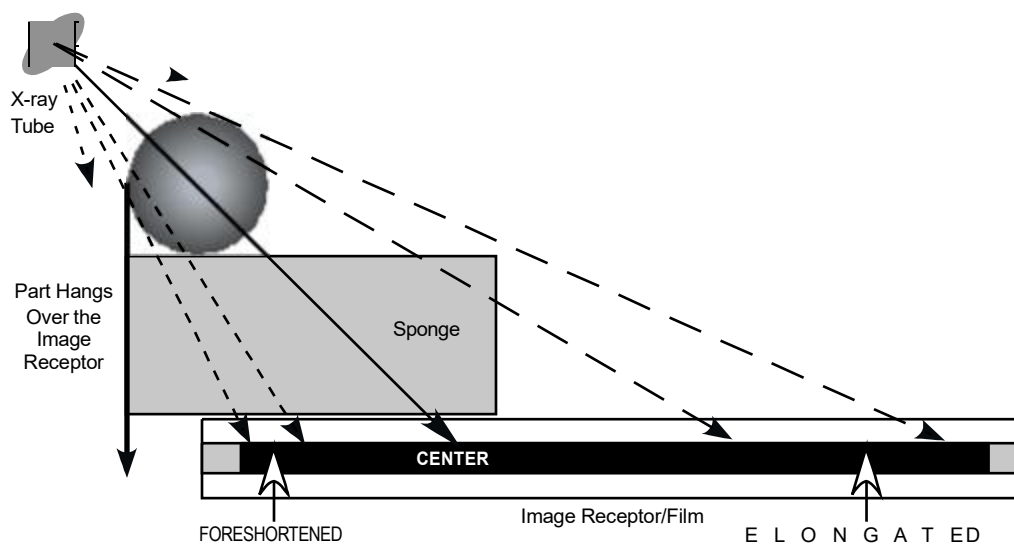
Central ray-part-image receptor alignment

For exams that require a tube angulation special care must be taken. The central ray should **NOT** be directed to the same point on the patient that would be used for a perpendicular x-ray beam; it **must be modified** so it will pass through the center of the part and the appropriate position on the image receptor.

When radiographing smaller objects, *pay very close attention to the aerial image being projected onto the tabletop*. The greater the tube angulation, the more important this is.

In the diagram below:

- the central ray is **NOT** perpendicular
- the part-image receptor relationship is **NOT GOOD**
- the central ray-part-image receptor relationship is **MODIFIED**
- compensation was made for the central ray angulation



When properly positioned, a visual inspection may give the *false impression* that the part is NOT on the image receptor (examine the left side of diagram above); don't forget the aerial image will be *"thrown"* in the direction of the tube angulation. In this example, the aerial image is projected toward the right.

Experimental Procedure

Effect of the CR Angulation and Projection on Shape Distortion

Instructions for Exposures 1- 9

1. Place the **whole body phantom on top of the radiographic table.**
2. Place an appropriate **direct radiography (FPD) digital image receptor** on the tabletop (TT) and set the SID as indicated in the technique worksheet.
3. Tape the appropriate lead markers onto the image receptor.
(The room, side and exposure number must be labeled on **all** radiographs.)
4. Direct the central ray to the **center** of the body part of interest.
5. Collimate the x-ray beam to the appropriate size.
6. Expose the digital image receptor using the technique in the worksheet provided.
7. Analyze the resultant radiograph from the perspective of shape distortion.

Important Rule of Thumb:

To maintain the correct SID, the distance from the x-ray tube to the tabletop must be reduced by 1 inch for every 7 degrees of angulation. (2.5 cm for every 7 degrees in the metric system)

AP Chest

	CR Angulation	kVp	mAs	SID	IR	Bucky TT
1	perpendicular			100 cm	DR	bucky
2	25° cephalic				DR	bucky
3	25° caudal				DR	bucky

AP Sacrum

	CR Angulation and Projection	kVp	mAs	SID	IR	Bucky TT
4	perpendicular				DR	bucky
5	15° cephalic				DR	bucky
6	15° caudal				DR	bucky

Knee AP

CR Angulation and Projection	kVp	mAs	SID	IR	Bucky TT
---------------------------------------	-----	-----	-----	----	-------------

7	CR perpendicular			100 cm	DR	bucky
8	25° cephalic				DR	bucky
9	25° caudal				DR	bucky

Worksheet

CR Angulation Degrees Cephalic or Caudal	Briefly describe the appearance of each image. Is the body part of interest foreshortened or elongated? What structures are better visualized?
---	---

1		
----------	--	--

2		
----------	--	--

3		
----------	--	--

4		
----------	--	--

5		
----------	--	--

6		
----------	--	--

7		
----------	--	--

8		
----------	--	--

9		
----------	--	--

